

Case Report

RE-MOTION™ total wrist arthroplasty for treatment of advanced stage of scaphoid non-union advanced collapse. Does excision of the entire scaphoid bone prevent impingement at terminal range of radial deviation?

Ingo Schmidt*

¹SRH Poliklinik Gera GmbH, Straße des Friedens 122, 07548 Gera, Germany

Abbreviations: SNAC: scaphoid non-union advanced collapse; PA: posteroanterior; OA: osteoarthritis; TWA: total wrist arthroplasty; TWF: total wrist fusion; PE: polyethylene.

Case presentation

A 57-year-old right-handed woman sustained a left scaphoid waist fracture that was primarily treated with immobilization in another hospital that led to a scaphoid non-union one year later (Figure 1A). Then, the scaphoid non-union was treated surgically with a use of a headless compression screw accompanied with autologous bone grafting in the same hospital. This procedure has been failed, there was a migration of the screw at the distal pole of collapsing scaphoid bone (Figure 1B). The screw was removed with a second procedure in the same hospital. At first presentation in our hospital three years after injury, the posteroanterior (PA) radiograph revealed advanced stage of scaphoid non-union advanced collapse (SNAC) accompanied with complete avascular osteonecrosis of the proximal pole of scaphoid bone leading to posttraumatic pancarpal wrist joint osteoarthritis (OA) (Figure 1C). A total wrist arthroplasty (TWA) using the RE-MOTION™ total wrist (Stryker Corporation, Kalamazoo, Michigan/USA) accompanied with removal of the entire scaphoid bone was performed. For this purpose, a straight carpal plate size S with a polyethylene (PE) insert size plus had to be applied that has had a sufficient bony support onto the capitate bone and did not lead to an impingement at terminal range of radial deviation with 15° (Figure 2A-B). The correct positioning of TWA was confirmed on postoperative radiographs (Figure 2C). At the 2-year follow-up there was unchanged correct positioning of TWA without implant loosening or subsidence, and an excellent functional outcome without impingement at terminal range of radial deviation with 30° radiographically (Figure 3). Function in patient-rated wrist evaluation score (0-100 points) and pain in visual analogue score (0-10 points) improved from 69 and 8 before TWA to 14 and 1. The patient reported that he would have the same motion-preserving TWA again if it would be necessary.

Non-union of a scaphoid fracture is consistently followed by the development of OA within 5-10 years [1]. Scaphoid fractures and/or non-unions are increasingly being managed surgically with the use of headless compression screws. However, this procedure is not without complications such as migration of a headless compression screw. It has been also observed in the wrist in 14% of patients who underwent carpal fusions despite complete union [2], and can lead in single case

to a TWA [3]. TWA has proven to be useful as a motion-preserving alternative to total wrist fusion (TWF) for treatment of posttraumatic wrist joint OA, and TWA revealed a significantly better outcome than in patients who underwent a primary TWF [4-6]. TWA for treatment of SNAC wrist has reported to be a relative portion of 4% of all TWAs performed by surgeons who have published their experiences with this procedure [7]. The RE-MOTION™ total wrist is one of the modern biaxial-anatomical third generation type that is currently in use. First, the development of the implant, its design, and early results with a small

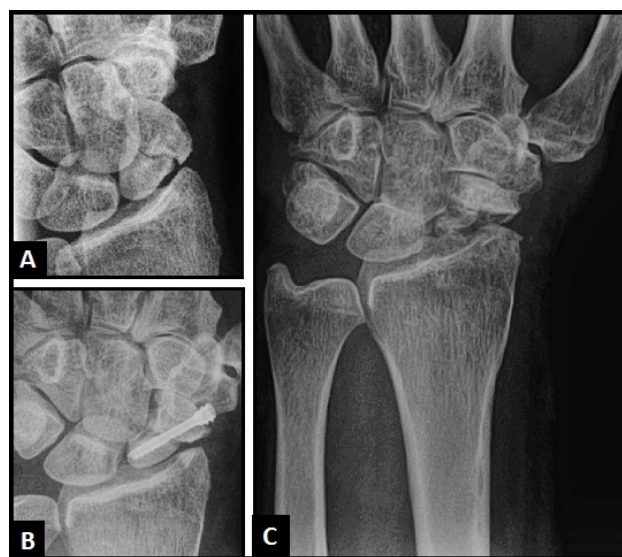


Figure 1. (A) PA radiograph showing scaphoid non-union; (B) PA radiograph showing migration of the headless compression screw at the distal pole of collapsing scaphoid bone; (C) PA radiograph showing posttraumatic pancarpal wrist joint OA due to advanced stage of SNAC wrist with complete avascular necrosis of the proximal pole of scaphoid bone.

Correspondence to: Ingo Schmidt, SRH Poliklinik Gera GmbH, Straße des Friedens 122, 07548 Gera, Germany, Tel: 00491789503035; E-mail: schmidtingo62@googlemail.com

Key words: scaphoid non-union advanced collapse, posttraumatic pancarpal wrist osteoarthritis, total wrist arthroplasty, impingement

Received: February 10, 2017; **Accepted:** March 07, 2017; **Published:** March 10, 2017

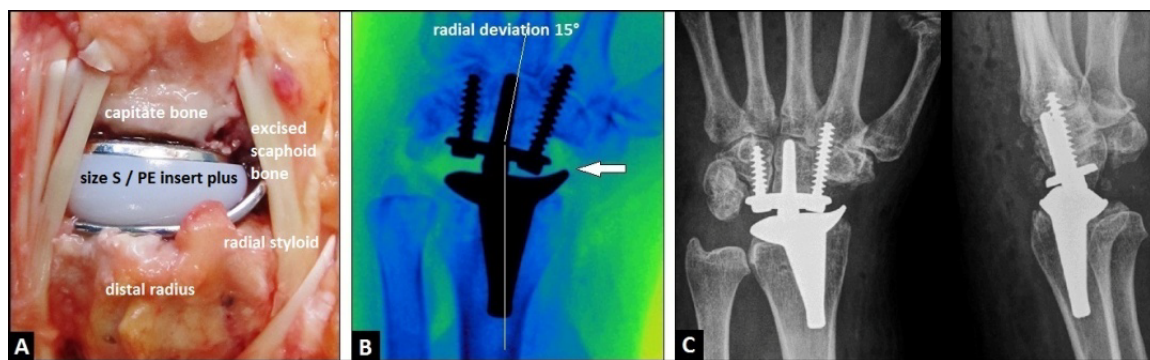


Figure 2. (A) Intraoperative photograph demonstrating uneventful insertion of the RE-MOTION™ TWA, the straight carpal plate size S has a sufficient bony support onto the capitae bone after excision of the entire scaphoid bone (B) Intraoperative fluoroscopy demonstrating that there was no impingement between the radial TWA component and the trapez bone at terminal range of radial deviation with 15° (arrow); (C) Postoperative PA and lateral radiographs demonstrating correct positioning of TWA. (PE: polyethylene).

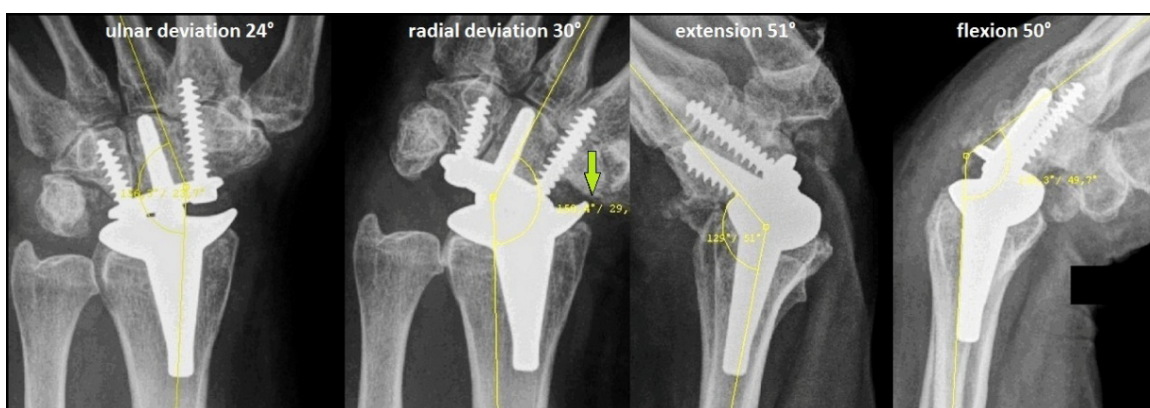


Figure 3. PA and lateral radiographs with terminal ranges of motion at the 2-year follow-up showing unchanged correct positioning of TWA without implant loosening or subsidence, and an excellent functional outcome without impingement at terminal range of radial deviation with 30° between the radial TWA component and the trapez bone after complete excision of the entire scaphoid bone (arrow), also noted that there is a sufficient bony support of the carpal plate size S at the capitae bone.

number of patients have been described in 2008 by Gupta [8]. Second, in 2011 Herzberg [9] published first encouraging short term results with a larger number of patients (N=19, 20 TWAs). Recent evidence with the use of the RE-MOTION™ total wrist revealed a cumulative 8-year implant surveillance of 92% in a prospective international multicenter study with 215 cases [10]. It seems to be a problem with the use of the RE-MOTION™ total wrist that radial deviation worsens postoperatively potentially leading to painful impingement between the radial TWA component and the distal part of scaphoid bone, whereas radial deviation with the use of the Maestro™ total wrist significantly improves [11-13]. An additional diagonal resection of the distal part of scaphoid is likely unable to avoid this impingement with the use of the RE-MOTION™ total wrist (Figures 4, 5) [14]. May be that this functional loss of the RE-MOTION™ total wrist is based on an insufficient compensation of resection-related loss of carpal height with its only available two sizes of height of the PE inserts (standard, plus).

We present one successful case on TWA using the RE-MOTION™ total wrist accompanied with excision of the entire scaphoid bone that did not lead to a painful impingement between the radial TWA component and the trapez bone. Essential prerequisite was that a carpal plate size S was inserted. Probably with the use of the other two bigger sizes (M, L) of the implant, the carpal plate would not have a sufficient bony support at the radial column. The disadvantage of the RE-MOTION™ total wrist is that its carpal plate is not available with various scaphoid augments such as the Maestro™ TWA that provides a sufficient bony support onto the base of trapez bone when the entire scaphoid bone had to be excised [3,5,15]. May be that the resection-related loss of carpal height using the RE-MOTION™ total wrist

would be better compensated by introducing of another extended third PE insert (“size plus-plus”) by the manufacturer. To our experience, the Maestro™ Wrist Reconstructive System with its three sizes of intercalated cobalt-chrome-molybdenum heads (standard, plus 2, plus 4) is better able to compensate the resection-related loss of carpal height that does not lead to an impingement between both TWA components [3,16,17]. Also noted that the carpal plate of the Maestro™ implant is longer in transverse plane and has a shaped design than the shorter carpal plate of the RE-MOTION™ total wrist with its straight design at the implant-bone interface (Figure 6, in comparison to Figure 2A-C). Radial impingement is also not observed with the Maestro™ Wrist Reconstructive System when using a carpal plate with scaphoid augment after excision of the entire scaphoid bone (Figure 7).

Acknowledgements

None.

Declarations

The author declares that he has none conflict of interests concerning this article.

References

1. Laulan J, Marteau E, Bacle G (2015) Wrist osteoarthritis. *Orthop Traumatol Surg Res* 101: S1-9. [Crossref]
2. Richards AA, Afifi AM, Moneim MS (2011) Four-corner fusion and scaphoid excision using headless compression screws for SLAC and SNAC wrist deformities. *Tech Hand Up Extrem Surg* 15: 99-103. [Crossref]
3. Schmidt I (2016) An Unusual and Complicated Course of a Giant Cell Tumor of the Capitae Bone. *Case Rep Orthop* 2016: 3705808. [Crossref]

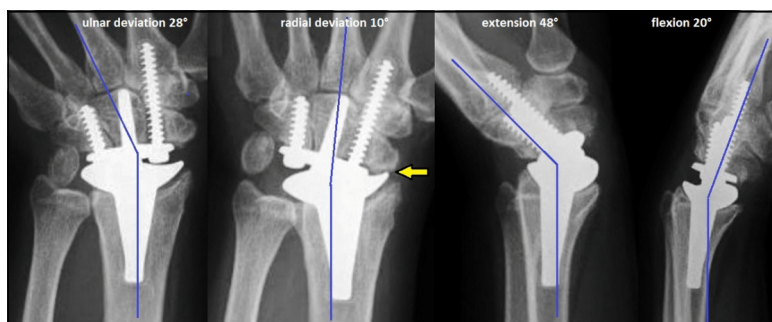


Figure 4. (Example for radial impingement): PA and lateral radiographs with terminal ranges of motion in a 54-year-old female with advanced stage of Kienböck’s disease in her left wrist treated with RE-MOTION™ TWA demonstrating impingement between the radial component and the distal part of scaphoid bone at terminal range of radial deviation with 10° (arrow) at the 3-year follow-up, a diagonal resection at the distal part of scaphoid bone was not done.

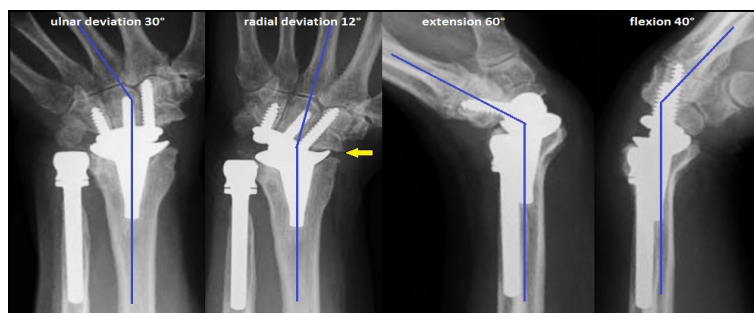


Figure 5. (Example for radial impingement): PA and lateral radiographs with terminal ranges of motion, this is the 3-year follow-up of the patient’s case with the longstanding distal radius physical arrest that was previously published at an 1-year follow-up by the author in 2014 [14], there is an impingement between the radial component of the RE-MOTION™ total wrist and the distal part of scaphoid bone at terminal range of radial deviation with 12°, a diagonal resection at the distal part of scaphoid bone was primarily done, also noted the periprosthetic bone resorption around the collar of the ulnar head replacement.

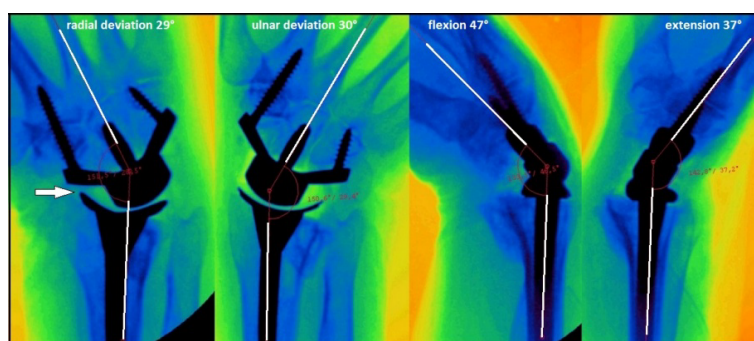


Figure 6. (Example for non radial impingement with the use of the Maestro™ Wrist Reconstructive System, carpal plate without scaphoid augment, the distal part of scaphoid bone was not excised): Intraoperative fluoroscopy in both planes with terminal ranges of motion in a 55-year-old male who sustained a TWA for treatment of advanced stage of right primary wrist joint OA, there is no impingement between both TWA components (i.e. radial styloid) at terminal range of radial deviation with 29° (arrow), the carpal plate has a sufficient bony support onto the distal part of scaphoid bone, also noted that the carpal plate is larger in transverse plane and has a shaped design than the shorter carpal plate of the RE-MOTION™ total wrist with its straight design at the implant-bone interface (see Figure 2), this intraoperative fluoroscopy is associated with the patient’s case that was previously published by the author in 2015 that did not show radial impingement at a 5-year follow-up as well [16].

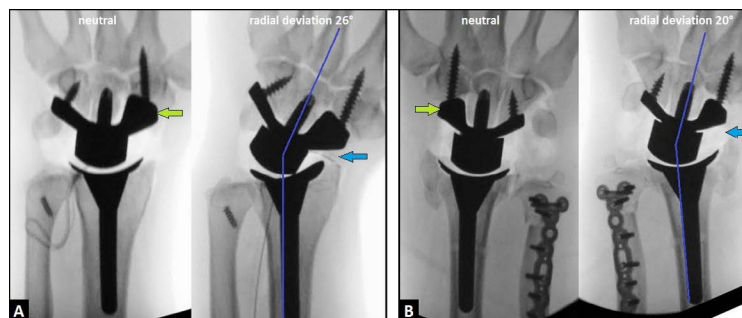


Figure 7. (Example for non radial impingement with the use of the Maestro™ Wrist Reconstructive System, carpal plates with scaphoid augments (green arrows), the entire scaphoid bones were excised): (A) Intraoperative fluoroscopy in a 31-year-old male who sustained a TWA due to advanced stage of posttraumatic wrist joint OA in his left wrist, there is no impingement between the carpal plate and radial component or radial styloid at terminal range of radial deviation with 26° (blue arrow); (B) Intraoperative fluoroscopy in a 56-year-old male who sustained a TWA for treatment of highly comminuted distal radius fracture in his right wrist, there is no impingement between the carpal plate and radial component or radial styloid at terminal range of radial deviation with 20° (blue arrow), this intraoperative fluoroscopy is associated with the patient’s case that was previously published by the author in 2015 that did not show radial impingement at an 1-year follow-up as well [17].

Schmidt I (2017) RE-MOTION™ total wrist arthroplasty for treatment of advanced stage of scaphoid non-union advanced collapse. Does excision of the entire scaphoid bone prevent impingement at terminal range of radial deviation?

4. Boeckstyns ME, Herzberg G, Sorensen AI, Axelsson P, Krøner K, et al (2013) Can total wrist arthroplasty be an option in the treatment of the severely destroyed posttraumatic wrist? *J Wrist Surg* 2: 324-329. [[Crossref](#)]
5. Schmidt I (2017) The Maestro™ Wrist Reconstructive System for treatment of posttraumatic wrist joint osteoarthritis after a devastating course of a distal radius fracture: Case presentation and technical note to the implant. *Trauma Emerg Care* 2: 1-4. [[Crossref](#)]
6. Nydick JA, Watt JF, Garcia MJ, Williams BD, Hess AV (2013) Clinical outcomes of arthrodesis and arthroplasty for the treatment of posttraumatic wrist arthritis. *J Hand Surg Am* 38: 899-903. [[Crossref](#)]
7. Boeckstyns ME (2014) Wrist arthroplasty--a systematic review. *Dan Med J* 61: A4834. [[Crossref](#)]
8. Gupta A (2008) Total wrist arthroplasty. *Am J Orthop (Belle Mead NJ)* 37: 12-16. [[Crossref](#)]
9. Herzberg G (2011) Prospective study of a new total wrist arthroplasty: short term results. *Chir Main* 30: 20-25. [[Crossref](#)]
10. Herzberg G, Boeckstyns M, Sorensen AI, Axelsson P, Kroener K, et al (2012) "Remotion" total wrist arthroplasty: preliminary results of a prospective international multicenter study of 215 cases. *J Wrist Surg* 1: 17-22.
11. Boeckstyns ME, Herzberg G, Merser S (2013) Favorable results after total wrist arthroplasty: 65 wrists in 60 patients followed for 5-9 years. *Acta Orthop* 84: 415-419.
12. Sagerfors M, Gupta A, Brus O, Rizzo M, Pettersson K (2015) Patient related functional outcome after total wrist arthroplasty: a single center study of 206 cases. *Hand Surg* 20: 81-87. [[Crossref](#)]
13. Nydick JA, Greenberg SM, Stone JD, Williams B, Polikandriotis JA, et al. (2012) Clinical outcomes of total wrist arthroplasty. *J Hand Surg Am* 37: 1580-1584. [[Crossref](#)]
14. Schmidt I (2014) Primary combined replacements for treatment of distal radius physeal arrest. *J Wrist Surg* 3: 203-205. [[Crossref](#)]
15. Dellacqua D (2009) Total wrist arthroplasty. *Tech Orthop* 24: 49-57.
16. Schmidt I (2015) Combined replacements using the Maestro total wrist and uHead ulnar head implants. *J Hand Surg Eur Vol* 40: 754-755. [[Crossref](#)]
17. Schmidt I (2015) Can Total Wrist Arthroplasty Be an Option for Treatment of Highly Comminuted Distal Radius Fracture in Selected Patients? Preliminary Experience with Two Cases. *Case Rep Orthop* 2015: 380935. [[Crossref](#)]

Copyright: ©2017 Schmidt I. This is an open-access article distributed under the terms of the Creative Commons Attribution License, which permits unrestricted use, distribution, and reproduction in any medium, provided the original author and source are credited.