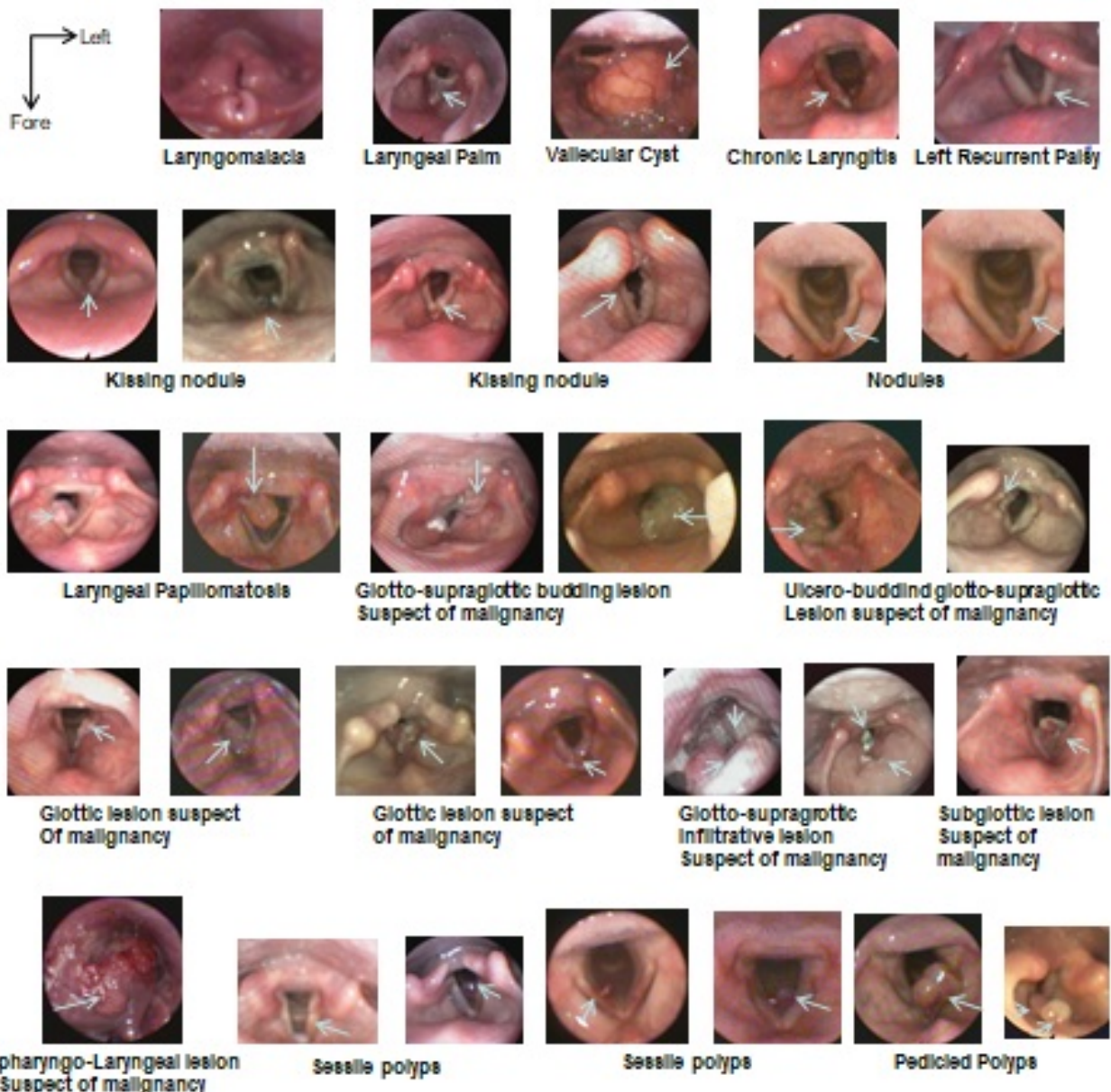


Panorama of laryngeal lesions

Diouf MS*, Deguenonvo REA, Thiam A, Maiga S, Diop A, Regone E, Barry MW and Diouf R

ENT department of Grand Yoff General Hospital in Dakar, Senegal



Copyright: ©2018 Diouf MS. This is an open-access article distributed under the terms of the Creative Commons Attribution License, which permits unrestricted use, distribution, and reproduction in any medium, provided the original author and source are credited.

***Correspondence to:** Mame Sanou Diouf, ENT department of Grand Yoff General Hospital in Dakar, Senegal, E-mail: sanou29@hotmail.com

Received: April 23, 2018; **Accepted:** April 28, 2018; **Published:** April 30, 2018