

## Case Report

# Congenital hyperinsulinemic hypoglycemia: Review of the Indian scenario

Kochar IS, Ramachandran S\* and Sethi A

Indraprastha Apollo Hospital, New Delhi, India

## Abstract

Congenital Hyperinsulinemic hypoglycemia (CHI) is a rare genetic disorder resulting severe hypoglycemia secondary to excessive insulin release from the pancreatic cells. Its early diagnosis is imperative to prevent irreversible brain damage by hypoglycemia. Genetic testing and 18-F-DOPA scan help to confirm the diagnosis.

We report the first heterozygous, paternally inherited ABCC8 missense mutation with focal pancreatic lesion from India and a review of the cases of CHI reported from India.

## Introduction

Congenital Hyperinsulinemic hypoglycemia (CHI) is a rare genetic disorder resulting severe hypoglycemia secondary to excessive insulin release from the pancreatic cells. It is the most common etiology for infantile persistent hypoglycemia [1]. It is one of the most serious causes of neonatal hypoglycemia and can cause irreversible brain damage if not treated on time and adequately.

It has an estimated prevalence of 1 in 50000 and almost 1 in 25000 to 1 in 3000 in countries with consanguineous marriage [2]. The mutations in ABCC8 and KCNJ11 are the most commonly found mutations, however several other mutations have been reported.

CHI can manifest as either focal due to adenomatous islet cell or diffuse lesions secondary to diffuse islet cell hyperplasia [3].

The outcome in the patient primarily depends upon the kind of lesion as the focal lesions benefit from local pancreatectomy whereas the diffuse lesions require extensive pancreatectomy resulting in diabetes in a lot of children in later life [4].

We report a case of CHI with an ABCC8 gene mutations and a detailed review of the cases reported from India and the gene mutations prevalent.

## Case report

This 2.7kg male baby was born at term to non-consanguineous parents by normal vaginal delivery. He was exclusively breast-fed and had no complaints for the first three days of life. On day 4 of life the child was excessively lethargic for which was taken to a hospital, where he was detected to have blood sugar of 40mg/dl. He was given glucose containing intravenous fluids and sent home thereafter.

On day 6 of life the baby had seizures and was taken to the emergency where he was diagnosed to have hypoglycemia without any ketonuria. His blood sugars were closely monitored, and dextrose was added to the breast feeds, however the baby continued to have several episodes of hypoglycemia and was referred to our hospital.

The critical blood sample taken at a time of hypoglycemia revealed C-peptide 2.72ng/ml, blood sugar 22mg/dl, serum insulin 13.3uU/ml, with thyroid, cortisol and growth hormone being in normal range. He was started on oral diazoxide at 10mg/kg/day and escalated to 15mg/kg/day for persisting hypoglycemia despite good compliance and regular blood sugar monitoring. The child was started on injectable subcutaneous octreotide at a dose of 2mcg/kg and increased to 4mcg/kg. Oral diazoxide was slowly tapered and stopped. A genetic study was done which showed that the child was heterozygous for the ABCC8 mutation missense variant, p.(Gly 111Arg). The father heterozygous for ABCC8 variant and the mother did not have any genetic mutations. The child was maintaining his blood sugar with octreotide and dextrose supplemented breast feeds. Although several ABCC8 mutations have been reported, a heterozygous, paternally inherited ABCC8 mutation missense variant, p.(Gly 111Arg) is the first case reported from India to the best of our knowledge.

An 18-Fluoro-DOPA scan detected an exophytic lesion 1.2cm x 0.8cm arising from the anterior part of the head of pancreas at the junction of the distal body and tail (Figure 1).

We followed up 18-F-Dopa with Ga extendin to diagnose and localize a focal lesion. It is a relatively new modality and confirmed the 18-F-Dopa findings in our case.

All the other Indian cases of ABCC8 mutation had diffuse involvement of the pancreas. This would be the first case of focal lesion at the pancreatic head with ABCC8 mutation in CHI to be reported from India.

\*Correspondence to: Smita Ramachandran, Fellow Pediatric and Adolescent Endocrinology Indraprastha Apollo Hospital, New Delhi, India, Ph: 9818488818; E-mail: smita\_rama25@yahoo.com

**Key words:** Congenital Hyperinsulinemic hypoglycemia (CHI), ABCC8, 18-F-DOPA, Indian cases, focal lesion

**Received:** September 07, 2018; **Accepted:** September 17, 2018; **Published:** September 21, 2018

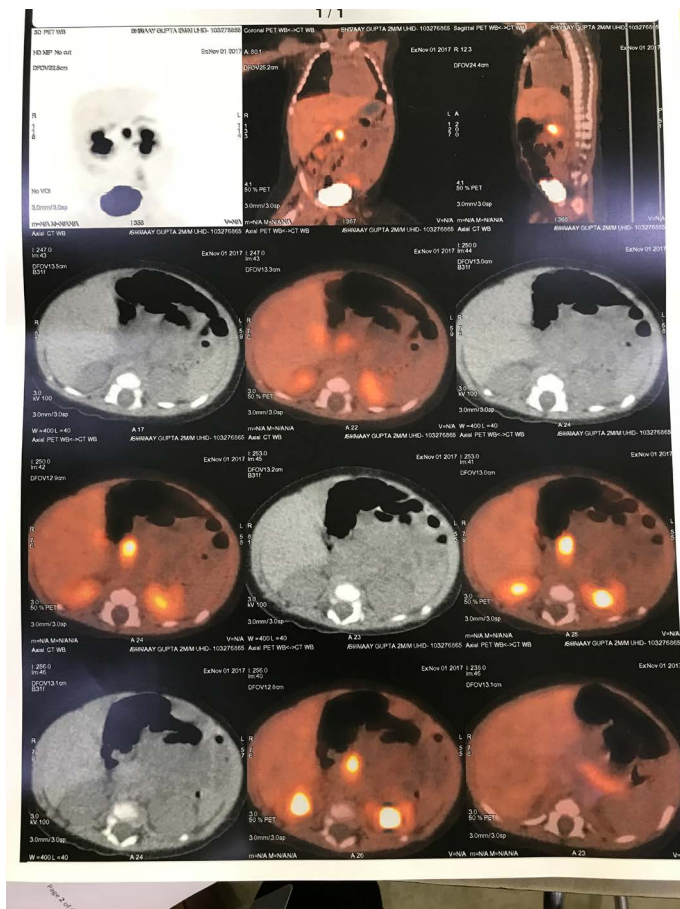


Figure 1. Congenital hyperinsulinemic hypoglycaemia

## Discussion

CHI is a heterogeneous genetic disorder of abnormal insulin secretion characterized by hyperinsulinism, hypoketonemia, and hypofattyacidemia with severe and persistent hypoglycemia.

CHI can occur due to two major defects: channelopathies and metabolopathies. Channelopathies refer to defects in the pancreatic  $\beta$ -cell ATP-sensitive KATP channel that results in unregulated insulin secretion. Metabolopathies cause congenital hyperinsulinemic hypoglycemia either by altering the concentration of intracellular signaling molecules (such as ATP/ADP) or by accumulation of intermediary metabolites, triggering the insulin release.

The Na K-ATPase pump and the metabolic nutrient state regulate the insulin activity in the body. Genetic mutations render the pump functionally inactive, hence causing the patients to be unresponsive to diazoxide, while some mutations may cause the pump to be inactive but responsive to pharmacological interventions.

The mutations that increase the nutrient metabolism and increase the ATP/ADP ratio and in turn increase the insulin secretion are the ones most responsive to diazoxide.

The most common mutations are the inactivating mutations of the  $\beta$ -cell ATP-sensitive K<sup>+</sup> channel genes ABCC8 (ATP-binding cassette subfamily C, member 8), which encodes for SUR1 (sulphonylurea receptor) and KCNJ11 (potassium inward rectifying channel, subfamily J, member 11), encoding Kir6.2 [5].

Genetic mutations have been identified in nine genes accounting for CHI resulting in either the diffuse or the focal form. Both autosomal dominant and recessive pattern have been demonstrated mostly in diffuse lesions resulting in the heterogeneity of presentation and severity. Focal ones are more sporadic.

It is hence very important to know the genetic mutations to predict the response to pharmacological interventions and their response in the affected children [6].

The most common mutations are the ABCC8 and KCNJ11, located next to each other on chromosome 11p. Till date there are 3 known Kir6.2 and over 40 SUR1 mutations that have been identified [6].

Few other mutations have also been identified and can be useful in predicting the type of pancreatic involvements and responsiveness to diazoxide.

The other common mutations seen are:

- glucokinase (encoded by GCK)
- glutamate dehydrogenase (GDH; encoded by GLUD-1 [glutamate dehydrogenase])
- mitochondrial enzyme short-chain 3-hydroxyacyl-CoA dehydrogenase (SCHAD); encoded by HADH [hydroxyacyl-coenzyme A dehydrogenase]

The K-ATP-sensitive potassium channel hyperinsulinism (K-ATP-HI) form caused by mutations in ABCC8 and KCNJ11 on chromosome 11, may cause autosomal recessive inheritance resulting in diffuse lesions and focal lesions due to loss of heterozygosity with paternal mutation. This type of resulting CHI is usually very severe and unresponsive to pharmacological treatment and requires pancreatectomy [7]. These babies are mostly large for gestation due to fetal overgrowth due to excessive insulin.

The dominant K-ATP-HI is inherited as autosomal dominant, it is milder and responsive to diazoxide.

GDH-HI (glutamate dehydrogenase hyperinsulinism), caused by GLUD-1 mutation on chromosome 10q is autosomal dominant. It is associated with hyperammonemia and responsive to diazoxide. The hallmark of GDH-HI is recurrent episodes of fasting and postprandial hypoglycemia associated with persistent asymptomatic elevation of plasma ammonia levels. These babies are not born large for gestation and remain asymptomatic at birth, manifest symptoms by several months of age [8].

GK-HI (glucokinase hyperinsulinism), due to GCK mutation on chromosome 7 is autosomal dominant and has a variable presentation, but most of them respond to diazoxide. It is relatively rare and has a varied age of presentation and severity of symptoms. The islet cell morphology can also range from normal cells to enlarged islets [9].

SCHAD-HI (short-chain 3-hydroxyacyl-CoA dehydrogenase hyperinsulinism), by HADH mutation on chromosome 4 is inherited as autosomal recessive. It has an abnormal acyl-carnitine profile and is usually diazoxide responsive. The biochemical markers are increased insulin action; increased levels of plasma 3-hydroxybutyryl-carnitine and increased levels of 3-hydroxyglutarate in urine. Despite having a fatty acid oxidation defect, children do not have hepatic dysfunction, cardiomyopathy, or effects on skeletal muscle [10] (Table 1).

Cases of CHI have been reported in a few case series and reports from India, but less than 25 gene mutations have been detected in

**Table 1.** Indian case of CHI

S.no	Study	Year	Nos.	Place	Genes /zygosity	Imaging
1	Kochar <i>et al.</i>	2017	1	Delhi	ABCC8/exon 3/Hetero	18-F-DOPA PET
2	Narayanan <i>et al.</i> [11]	2016	16	Chennai	-	DOTONAC-5 Gallium-1
3	Satapathy <i>et al.</i> [12]	2016	1	Delhi	HADH-exon 5	-
4	Rakesh kumar <i>et al.</i> [13]	2015	1	Delhi	-	DOTANOC
5	Khawash <i>et al.</i> [14]	2015	1	Kolkatta	ABCC8/hetero	-
6	Jahnvi <i>et al.</i> [15]	2014	22	Delhi	12 ABCC8 detected (2-exon1-hetero 1-exon3-homo 1-exon 5-hetero 1-exon 8 1-exon 12 1-exon 16-homo 1-exon 21 1-exon 22 1-IVS 30 1-exon 36-hetero	18-F-DOPA PET
7	Varadarajan <i>et al.</i> [16]	2014	15	Chennai	4-ABCC8	Gadolinium scan
8	Jindal <i>et al.</i> [17]	2014	1	Delhi	ABCC8/exon 5	
9	Dinesh Yadav <i>et al.</i> [18]	2012	1	Delhi	ABCC8-Intron 31	Ga-DOTANOC
10	Seema Thakur <i>et al.</i> [19]	2011	1		ABCC8-exon 2,3	-
11	Desai <i>et al.</i> [20]	1997	13	Mumbai	-	-

these cases in the last decade. Our case had a heterozygous, paternally inherited ABCC8 mutation missense variant, p.(Gly 111Arg). The only other case with the same ABCC8 mutation was reported by Jahnvi *et al.* [15], their case was however homozygous with a diffuse lesion requiring subtotal pancreatectomy and later went on to develop diabetes mellitus.

Vardarajan from Chennai [16] reported four cases of CHI with ABCC8 mutations, and these one was a paternally derived heterozygous mutation and the Gadolinium scan was suggestive of a diffuse disease. The other two were homozygous.

This case reported by us, however had a focal lesion at the anterior part of the head of pancreas at the junction of the distal body and tail. Both the previous cases of heterozygous ABCC8 mutation reported by Jahnvi *et al.* and Vardarajan *et al.* had a diffuse pancreatic involvement, one which required subtotal pancreatectomy. This would be the first case to be reported from India with an ABCC8 mutation of heterozygous inheritance with a focal pancreatic lesion.

## Management

The first line of treatment for congenital hyperglycemia is complicated and needs to be carefully titrated to balance the benefits and adverse effects. Diazoxide, a KATP channel agonist, is the mainstay of medical treatment in prolonged hyperinsulinemic hypoglycemia. It inhibits insulin secretion by keeping KATP channels open. It is administered at a dose of 10-20 mg/kg/day, orally, in three divided doses. Lower doses are required in small for gestation babies [21].

In cases resistant to diazoxide, Octreotide, a somatostatin analogue is used. It causes inhibition of insulin release by activation of somatostatin receptor-5, stabilizing KATP channel and inhibition of calcium mobilization. Lanreotide a long acting release octreotide has been proven to be of benefit in a few articles. It is suggested as a once a month intramuscular dose [22].

However, the treatment for diazoxide resistant and diffuse type mostly require surgery. So, it becomes imperative to have an accurate diagnosis and site of lesions to execute affective treatment. Ultrasound,

computed tomography (CT), and magnetic resonance imaging (MRI) are usually non-discriminatory for the purpose of diagnosing and localizing focal CHI.

18-Fluoro-DOPA traces a very specific metabolic pathway and has a very precise biodistribution pattern, making it superior to both the above-mentioned non-invasive techniques and also to pancreatic venous sampling (PVS) and combined selective pancreatic arterial calcium stimulation and hepatic venous sampling (ASVS) [23]. The uptake of amine precursors of 18-F-DOPA is much more pronounced in hyperfunctioning islets, thus making the anatomic delineation much more specific.

Ga-exendin is a new modality that can prove potentially beneficial in detecting pancreatic lesion in PET tracer. It is a glucagon like peptide-1 receptor (GLP-1R) that is expressed on the  $\beta$ -cell of the pancreas. The endogenous peptide GLP-1 has a very short biological half-life and is very sensitive tool. However, it has been primarily used for diagnosing insulinomas worldwide.

## Conclusion

CHI is a complicated disease, which requires prompt diagnosis to initiate treatment to prevent irreversible hypoglycemic brain damage. Genetic testing and 18-F-DOPA should be used in conjunction for diagnosis and prognosis.

Once the genetic testing confirms the diagnosis, 18-F-DOPA pinpoints the site of pancreatic lesion; appropriate treatment can be planned for diazoxide responsive and unresponsive cases.

Informed consent has been taken from the parents for publication of this case report.

## Funding

No funding

## Acknowledgements

Dr Chandrasekhar Bal, Department of Nuclear Medicine and PET, All India Institute of Medical Sciences, New Delhi.

Dr Rajesh Khadgawat, Pediatric and Adolescent Endocrinology Clinic, All India Institute of Medical Sciences

New Delhi.

For genetic testing of the case and parents: University of Exeter Royal, Devon and Exeter NHS Foundation Trust

### Conflict of interest

None

### Author contribution

SR and AS have researched compiled the data and the review. IPS reviewed the whole article and supervised the whole process.

### References

- Chandran S, Peng FY, Rajadurai VS, Lu YT, Chang KT, et al. (2013) Paternally inherited ABCC8 mutation causing diffuse congenital hyperinsulinism. *Endocrinol Diabetes Metab Case Rep.* 2013:130041. [Crossref]
- Mathew PM, Young JM, Abu-Osba YK, Mulhern BD, Hammoudi S, et al. (1988) Persistent neonatal hyperinsulinism. *Clin Pediatr (Phila)* 27: 148-151. [Crossref]
- Rahier J, Fält K, Müntefering H, Becker K, Gepts W, et al. (1984) The basic structural lesion of persistent neonatal hypoglycaemia with hyperinsulinism: deficiency of pancreatic D cells or hyperactivity of B cells? *Diabetologia* 26: 282-289. [Crossref]
- Leibowitz G, Glaser B, Higazi AA, Salameh M, Cerasi E, et al. (1995) Hyperinsulinemic hypoglycemia of infancy (nesidioblastosis) in clinical remission: high incidence of diabetes mellitus and persistent  $\beta$ -cell dysfunction at long-term follow-up. *J Clin Endocrinol Metab* 80:386-392
- Glaser B, Thornton P, Otonkoski T, Junien C (2000) Genetics of neonatal hyperinsulinism. *Arch Dis Child Fetal Neonatal Ed* 82: F79-86. [Crossref]
- Aguilar-Bryan L, Bryan J (1999) Molecular biology of adenosine triphosphate-sensitive potassium channels. *Endocr Rev* 20: 101-135. [Crossref]
- De León DD, Stanley CA (2007) Mechanisms of Disease: advances in diagnosis and treatment of hyperinsulinism in neonates. *Nat Clin Pract Endocrinol Metab* 3: 57-68. [Crossref]
- Hsu BY et al. (2001) Protein-sensitive and fasting hypoglycemia in children with the hyperinsulinism/ hyperammonemia syndrome. *J Pediatr* 138: 383-389
- Cuesta-Muñoz AL, Huopio H, Otonkoski T, Gomez-Zumaquero JM, Näntö-Salonen K, et al. (2004) Severe persistent hyperinsulinemic hypoglycemia due to a de novo glucokinase mutation. *Diabetes* 53: 2164-2168. [Crossref]
- Molgen A, Matre GE, Duran M, Wanders RJ, Rishaug U, et al. (2004) Familial hyperinsulinemic hypoglycemia caused by a defect in the SCHAD enzyme of mitochondrial fatty acid oxidation. *Diabetes* 53: 221-227. [Crossref]
- Narayanan E, Kumutha J (2016) Persistent Hyperinsulinism - Hyperinsulinemic Hypoglycemia : Follow up and Review of 16 Cases. *Indian journal of applied research.* 6:385-87
- Satayapathi A, Vandana J, Ellard, Flanagan E (2016) Hyperinsulinemic Hypoglycemia of Infancy due to Novel HADH Mutation in Two Siblings. *Indian Pediatr.* 53:912-913. [Crossref]
- Gupta RK, Saran RK, Debnath PR, Chadha R (2015) Is histopathology informative for further characterization of DOTANOC-proven islet cell lesions in infancy?. *Indian J Pathol Microbiol* 58:410-412. [Crossref]
- Papiya Khawash, Khalid Hussain, Sarah E. Flanagan, Sudip Chatterjee, Basak D (2015) Nifedipine in Congenital Hyperinsulinism- A Case Report. *J Clin Res Pediatr Endocrinol.* 7: 151-154. [Crossref]
- Jahnavi S, Poovazhagi V, Kanthimathi S, Balamurugan K, Bodhini D, et al. (2014) Novel ABCC8 (SUR1) Gene Mutations in Asian Indian Children with Congenital Hyperinsulinemic Hypoglycemia. *Ann Hum Genet* 78: 311-319. [Crossref]
- Varadarajan P, Ananthanarayanan K, Mirra K, Jahnavi S, Venkatesan R, et al. (2014) Clinical Profile and Outcome of Persistent Hyperinsulinemic Hypoglycemia of Infancy. *Pediatric Oncall Journal* 11
- Yadav D, Dhingra B, Kumar S, Kumar V, Dutta AK (2012) Persistent hyperinsulinemic hypoglycemia of infancy. *J Pediatr Endocr Met* 25:591-593
- Jindal R, Ahmad A, Siddiqui MA, Kochar IS, Wangnoo SK (2014) Novel mutation c.597\_598dup in exon 5 of ABCC8 gene causing congenital hyperinsulinism. *Diabetes Metab Syndr.* 8:45-47. [Crossref]
- Thakur S, Flanagan S, Ellard S, Verma IC (2011) Congenital Hyperinsulinism Caused by Mutations in ABCC8 (SUR1) Gene. *Indian Pediatrics.* 48:733-734. [Crossref]
- Desai MP, Khatri KV (1998) Persistent hyperinsulinemic hypoglycemia of infancy. *Indian paediatrics.*
- Tas E, Mahmood B, Garibaldi L, Sperling M (2015) Liver injury may increase the risk of diazoxide toxicity: a case report. *Eur J Pediatr* 174: 403-406. [Crossref]
- Modan-Moses D, Koren I, Mazor-Aronovitch K, Pinhas-Hamiel O, Landau H (2011) Treatment of congenital hyperinsulinism with Lanreotide acetate (Somatuline Autogel). *J Clin Endocrinol Metab.* 96:2312-2317. [Crossref]
- Blomberg BA, Moghbel MC, Saboury B, Stanley CA, Alavi A (2013) The Value of Radiologic Interventions and 18F-DOPA PET in Diagnosing and Localizing Focal Congenital Hyperinsulinism: Systematic Review and Meta-Analysis. *Mol Imaging Biol.* 15: 97-105.

**Copyright:** ©2018 Kochar IS. This is an open-access article distributed under the terms of the Creative Commons Attribution License, which permits unrestricted use, distribution, and reproduction in any medium, provided the original author and source are credited.