

# Pregnancy After Orthotopic Ovarian Tissue Transplantation Using N-Hexyl-2-Cyanoacrylate as A Tissue Adhesive

Francisco Fàbregues\*, Josep M. Calafell, Dolors Manau, Aina Borràs, Joana Peñarrubia, Gemma Casals, Sara Peralta, Montserrat Creus, Janisse Ferreri, Roser Solernou and Francisco Carmona

Institut Clinic Gynecology, Obstetrics and Neonatology

## Abstract

Cryopreservation of ovarian tissue in advance of cytotoxic therapies and later transplantation of the tissue is being performed increasingly often, and the total success rates in terms of pregnancy and delivery have been described in case series. Most pregnancies were achieved after orthotopic transplantation of tissue (in the peritoneum or the remaining ovary) however treatment of the transplantation site during surgery is controversial. In this observational case-series study we include four patients to whom ovarian tissue transplantation was performed between 2012 and 2016 by laparoscopy. Previously ovarian tissue was cryopreserved with slow freezing protocol prior to chemo-and/or radiotherapy. After cancer remission, the cryopreserved ovarian tissues were retransplanted orthotopically in the ovarian medulla by laparoscopy, using n-hexyl-2-cyanoacrylate as an absorbable adhesion barrier. All patients regained ovarian function between 8 and 24 weeks after transplantation, as shown by follicle development and estrogen production. In patients 1 and 2 the ovarian function ended one year after transplantation. Patient 3 has regular menstrual cycles 2 years after the transplant and patient 4 currently has an ongoing spontaneous pregnancy.

The use of N-hexyl-2-cyanoacrylate can facilitate the placement of ovarian pieces in the orthotopic transplantation by laparoscopy without affecting the restoration and duration of ovarian activity.

## Introduction

The past four decades have seen substantial improvements in the long-term survival of both children and adults with cancer, leading to the development of the services to optimize long-term health after successful treatment. The potential loss of fertility for some cancer survivors is a major concern of patients, and in the case of children, of their parents. As a result of improvements in oncologic treatment, the majority of younger cancer patients are now achieving prolonged survival [1]. However, loss of ovarian function and therefore fertility is one of the most common long-term adverse effects affecting premenopausal patients treated with chemotherapy and/or radiation therapy. A number of strategies have been developed in recent years to enable these patients to have children using their gametes. When chemotherapy can be postponed, it is possible to use ovarian stimulation to obtain oocytes, which can be frozen in either a fertilized or an unfertilized state [2,3].

The removal of ovarian tissue prior to starting oncologic treatment and the subsequent transplantation of this tissue after completing therapy have become increasingly important surgical fertility-preserving techniques [4-6]. At least 86 live births have been reported worldwide [7]. The procedure has been incorporated into numerous national and international networks and programmes (Oncofertility Consortium; FertiProtekt; International Society for Fertility Preservation), a technique which is no longer experimental according to the criteria by ESHRE Special Interest Group `Ethics and Law [8]. Nevertheless, some professional societies such as the American Society for Reproductive Medicine still consider ovarian tissue freezing to be an experimental technique [9]. Different surgical techniques can be used

both for ovarian biopsy and for the transplantation of ovarian tissue. A number of different surgical routes have been used, and the amount of tissue extracted, the instruments used, the treatment of the ovary, the transplantation site, the blood supply to the transplanted ovarian tissue and the procedure used for simultaneous surgical interventions vary [10,11].

The pelvic cavity (orthotopic site) provides the optimal environment for follicular development compared with heterotopic sites. Two techniques were successfully used to reimplant frozen-thawed ovarian tissue in an orthotopic site: either in a specially created window on the peritoneum or on the remaining ovary. In case of small fragments they can be placed on the decorticated medulla but is particularly difficult when performed laparoscopically. The use of tissue adhesives as cyanoacrylates can facilitate the laparoscopy orthotopic transplantation.

The aim of this study was to examine the usefulness of N-hexyl-2-cyanoacrylate in the laparoscopic orthotopic ovarian transplantation analyzing the restoration of ovarian activity and reproductive outcome of the patients.

**Correspondence to:** Francisco Fàbregues, Institut Clinic Gynecology, Obstetrics and Neonatology HospitalClinic, Barcelona, Spain, E-mail: fgasol@clinic.ub.es

**Key words:** Cyanoacrylate, fertility preservation, orthotopic transplantation, ovarian tissue transplantation

**Received:** December 10, 2017; **Accepted:** December 26, 2017; **Published:** December 29, 2017

**Patients and methods**

**Patients**

In this observational case-series study we include four patients to whom ovarian tissue transplantation was performed between 2012 and 2016 by laparoscopy. The ethics committee of the hospital approved the study, and all patients provided written informed consent. Table 1 presents the diagnosis and age of 4 women undergoing ovarian tissue cryopreservation and transplantation with frozen/thawed ovarian tissue.

**Patient 1**

In 2010 a 39-year-old was diagnosed of nasopharyngeal carcinoma . Ovarian tissue cryopreservation was carried out before radio and chemotherapy . She became amenorrheic shortly after initiation of chemotherapy. Levels of follicle-stimulating hormone (FSH), luteinizing hormone (LH), and estradiol were, 92.3 mIU/ml, 82.5 mIU/ml, and 15 pg/ml respectively following chemo and radiotherapy, confirming castration. This ovarian failure profile was confirmed 3 months later.

In 2012, the patient expressed a desire to conceive. She present amenorrhea and FSH levels were > 100 mIU/ml. Orthotopic ovarian tissue transplantation was performed by laparoscopy placing 8 pieces of ovarian thawed in the medulla of contralateral ovary to the biopsy. Six months later, a first estradiol peak was detected, with a concomitant decline in FSH. Ultrasonography revealed the development of a follicle with each cycle. Restoration of consecutive menstrual bleeding was observed, and the patient was encouraged to have regular sexual intercourse. In one cycle when follicle reached 18 mm, HCG was added, and follicle aspiration was performed 36 hours later. A single mature egg was retrieved and fertilized with de husband’s sperm in vitro. On day two postfertilization, a four-cell embryo was transferred to the uterus. Pregnancy was not achieved. This obviously prevents exact knowledge on whether the oocyte was originated in the transplanted tissue or not, and this is a limitation which we want to acknowledge.

Twelve months after transplantation FSH levels increasing and the patient presented menstrual irregularity and absence follicular development by ultrasound was observed.

**Patient 2**

In 2002 a 35-year-old was diagnosed of breast cancer. Ovarian tissue was removed by laparoscopy for cryopreservation before the chemotherapy. She became amenorrheic 3 months after initiation of chemotherapy. Levels of follicle-stimulating hormone (FSH), luteinizing hormone (LH), and estradiol were 75.3 mIU/ml, 45.5 mIU/ml, and 18 pg/ml respectively, confirming ovarian failure.

In 2012, the patient, now wishing to conceive. The FSH levels were >100mIU/ml and became amenorrheic. Orthotopic ovarian tissue transplantation was performed by laparoscopy placing 9 pieces of

ovarian thawed in the medulla of contralateral ovary. Four months after reimplantation restoration of menstrual bleeding was observed and spontaneous follicle development was proved by vaginal untrasound. The ovarian activity remained regular until one year after the transplantation. Finally FSH levels increased and became amenorrheic.

**Patient 3**

The patient was diagnosed with breast cancer in 2011 at 35 years of age. Ovarian tissue was removed simultaneously during breast cancer surgery. She was amenorrheic from her third chemotherapy cycle and her sèrum FSH and AMH levels were 45.3 mIU/ml and 0.1 ng/ml respectively.

Ovarian tissue transplantation was performed in 2014. Eight pieces of frozen-thawed were placed to the ovarian medulla by laparoscopy. Two months after reimplantation, spontaneous follicle development was observed by ultrasonography and basal FSH was 7.9 mIU/l. After regular intercourse without pregnancy IVF modified natural cycle was performed in three cycles. In our institution, this protocol attempts to allow spontaneous growth of the dominant follicle without administration of any additional drug that may distort folliculogenesis or modify endometrial receptivity. However, in case of spontaneous LH surge (defined as an LH value that exceeds 180% of the mean baseline value) on the day of hCG, supplementary administration of 0.25 mg SC injection of a GnRH antagonist was given to prevent premature ovulation before oocyte retrieval. In case an LH surge was identified before a dominant follicle reached 15 mm, GnRH antagonist and 75 IU of SC gonadotropin/menotropin were used daily until triggering criteria were present. When follicle reached 18 mm, HCG was added, and follicle aspiration was carried out 36 hours later [12]. In each of the cycles one embryo was transferred without success. Two years after transplantation maintains regular menstrual cycles.

**Patient 4**

In 2011, a 32 year-old women was diagnosed of breast cancer. Breast surgery and laparoscopic ovarian preservation procedure was done in the same setting. She was amenorrheic from her third chemotherapy cycle and blood tests showed menopausal hormone values (FSH 82mUI/ml).

In May 2016 we performed orthotopic ovarian tissue transplantation placing fifteen pieces of frozen-thawed còrtex to the left ovarian medulla. Two months after reimplantation the patient presented her first menstruation and she became pregnant naturally which was confirmed positive by HCG in urine .The vaginal ultrasound revealed a viable intrauterine pregnancy and currently she is 31 weeks pregnant.

**Operative Technique**

We always used a laparoscopic approach to extract ovarian tissue. For the removal of the ovarian cortex we use scissors avoiding the use of coagulation to minimize the surgical trauma to the sensitive ovarian tissue. The bipolar coagulation should only be carried out after the samples of ovarian tissue had been removed and that coagulation should be done sparingly to protect the ovarian remnant.

We opted to remove 1/3 of the ovarian cortex which was cut into 5x5 mm fragments, rinsed with an isotonic saline solution and cryopreserved as the method previously described by Schmidt [13]. Briefly, the fragments were transferred to the freezing solution (0.1 mol/l sucrose and 1.5 mol/l ethylenglycol in phosphate-buffered saline) and equilibrated for 30 min at 1°C. The fragments were stored in 1.8

**Table 1.** Patients characteristics and time of orthotopic transplantation.

Patient	Indication	Age at tissue cryopreservation (date)	Age at transplantation	Restoration of ovarian activity (weeks)
1	Nasopharyngeal cancer	39 (21/04/10)	41	24
2	Breast cancer	35 (21/01/02)	45	16
3	Breast cancer	35 (09/02/11)	38	8
4	Breast cancer	32 (27/10/11)	37	8

ml cryovials (Nunc AS, Roskilde, Denmark) with cryoprotectant and cryopreserved using a programmable freezer (Planner K10, Planner Ltd., UK). Two fragments were submitted for histological study demonstrating the presence of primordial follicles and to rule out neoplastic cells.

The auto transplantation was performed by laparoscopy. A longitudinal incision in the ovarian cortex contralateral to the biopsy was performed. The fragments were rapidly thawed in a 37°C water bath and rinsed with thawing solutions with decreasing concentrations of cryoprotectants. The incision was made with scissors avoiding the use of electric coagulation. After exposing the medulla, we placed ovarian tissue and the n-hexyl-2-cyanoacrylate is applied as a surgical adhesive. Finally, once the fragments were fixed the edges of the ovary were approached using the same material. (Figures 1-4).

## Results

All patients were discharged the same day of the surgery. Restoration of ovarian function was observed in all cases between 8 and 24 weeks after the transplantation by the significant decrease in FSH levels compared to preoperative values (Figure 5).

The time interval between implantation and the restoration of ovarian activity could be explained by a difference in follicular reserve at the time of cryopreservation. Age would explain the observed differences and also the fact that patients 1 and 2 had a shorter duration of restored ovarian activity. This early restoration of ovarian activity initiated 2 months after transplantation could indicate that the follicular activity would come from the native ovary. It has recently been suggested that after transplantation there would be a massive recruitment of “trapped” follicles in the residual ovary may be mediated by mechanism via PTEN [14-16].

Figure 6 summarizes the follicular activity that was echo graphically verified and the oocyte recovery in the cycles in which in vitro fertilization was performed in the non-stimulated cycle. In none of these cycles, pregnancy was achieved. There is no doubt that the percentage of abnormal oocytes (immature or degenerated) is much higher in frozen-thawed transplanted tissue than in the general population undergoing IVF (Figure 6).

Patient 4 presented spontaneous follicle development 8 weeks after transplantation and she became pregnant naturally three months after ovarian transplantation and highlighting that assisted reproductive techniques are not necessary for most women (Figure 7).

## Discussion

This report describes our experience with the use of N-hexyl-2 cyanoacrylate as a fixation surgical treatment in the transplantation site during orthotopic ovarian tissue transplantation. To our knowledge this is the first experience with this synthetic surgical adhesive.

The extraction of ovarian tissue prior to commencing oncologic therapy and the subsequent re-implantation of this tissue after concluding cancer treatment is an innovative method which is becoming increasingly important in fertility surgery. A large number of centers have started to offer this procedure to affected women. The literature shows that the number of pregnancies and births following the transplantation of cryopreserved ovarian tissue has increased continually in recent years, indicating that this has become an established procedure [7,17,18]. Nevertheless, data on the best surgical technique for this fertility-preserving method is limited.

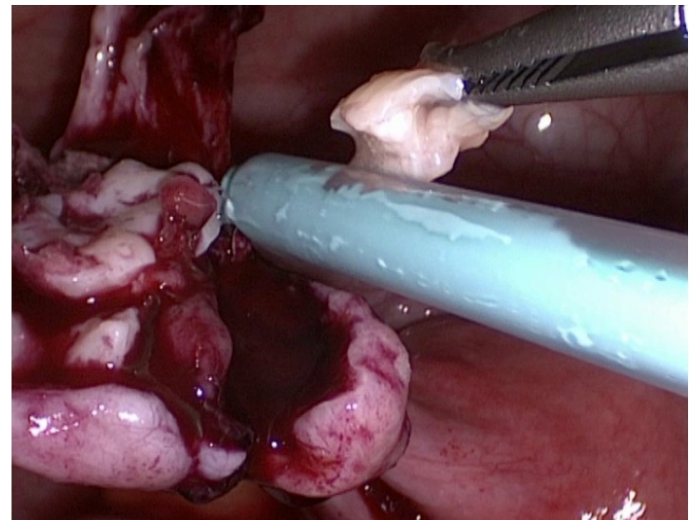


Figure 1. Placement of n-hexyl-cyanoacrylate on the decorticated ovarian medulla.

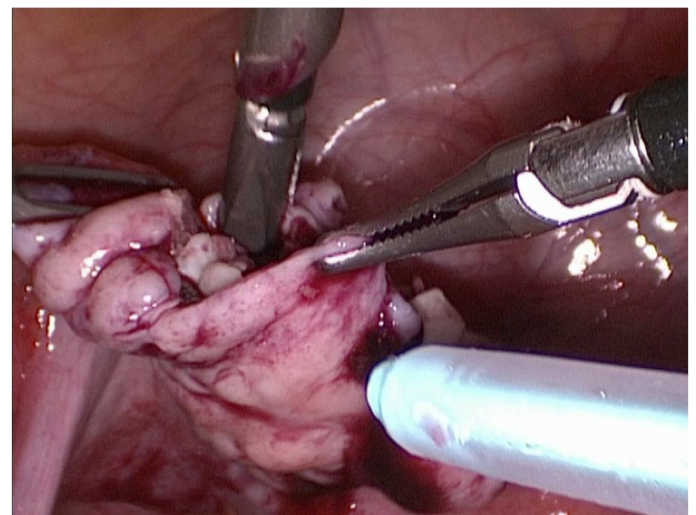


Figure 2. Placement of ovarian fragments

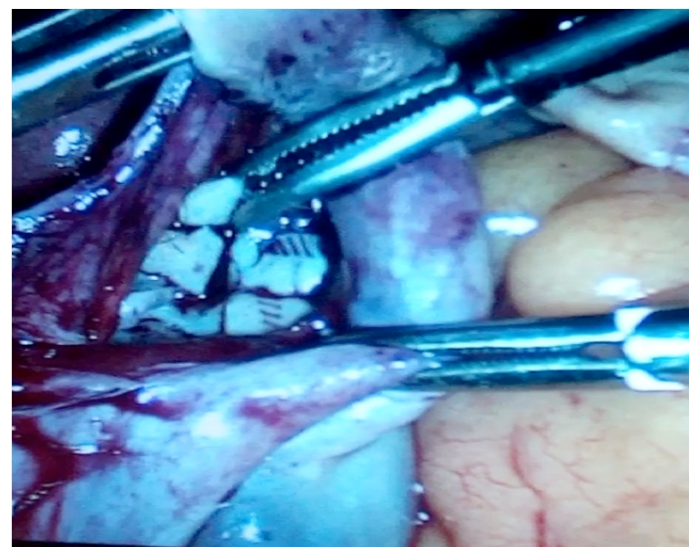


Figure 3. Ovarian fragments are visible on the remaining ovary

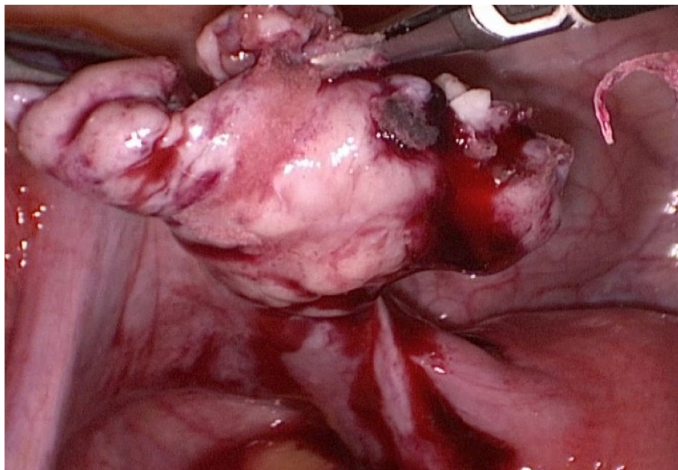


Figure 4. Bonding the edges of the ovary

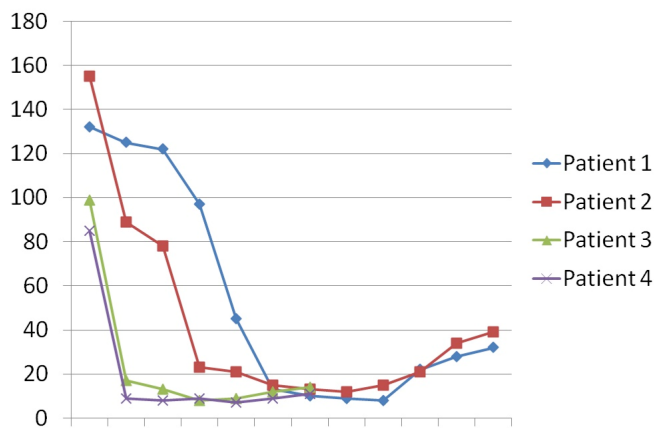


Figure 5. FSH values after orthotopic reimplantation of frozen-thawed ovarian tissue

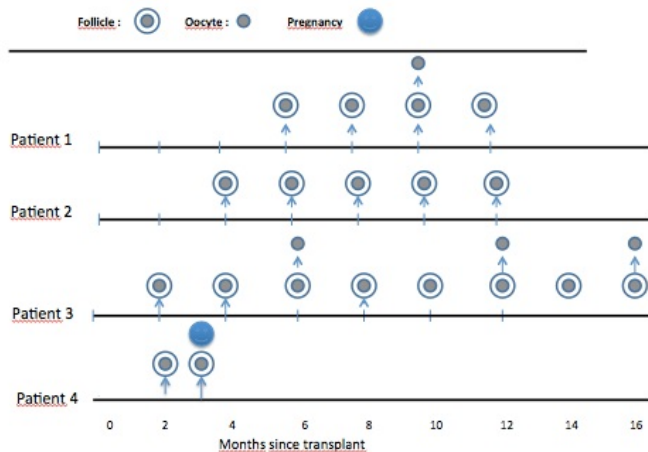


Figure 6. Double circles represent preovulatory follicle whereas single circles represent retrieved oocytes

The age is an important predictor of successful ovarian tissue transplantation, however there are published case series in which transplants have been performed in women of advanced ages achieving subsequent pregnancies. It can be assumed that individual ovarian reserve and thus follicle density at the time of tissue harvesting have greater influence than merely the patient's age at tissue harvesting [7,17].

Although the majority of centers opt for the laparoscopic approach for ovarian tissue transplantation, it is true that the laparotomic route has been successfully used by some authors (Silber, 2016). The benefit of the laparoscopic approach is that patients are fast operative recovery and can even be discharged on the day of surgery, allowing them to start chemotherapy without further delay [17-19].

Opinion is more divided on the question of the amount of ovarian tissue to be extracted. Donnez et al. pointed out that biopsies of the ovarian cortex need to be at least 1 mm thick, otherwise they not include primordial follicles under the mesothelium [20]. Other centers prefer ovarian sampling with sample sizes ranging 1/3 to 2/3 of the ovary [11,19] or even extraction of an entire ovary. The sampling of a large piece of ovarian tissue offers the opportunity to potentially carry out repeat transplantations of different portions, which could help maintain reproductive and endocrine ovarian function for longer. A possible compromise between the different approaches of the centers could consist of removing a large part of one ovary prior to scheduled aggressive chemotherapy but leaving more tissue in situ when protocols are less toxic [16].

Regarding ovarian cryopreservation techniques the great majority of pregnancies have occurred following slow freezing of the ovarian cortical pieces; however recent studies indicate that vitrification may have advantages. In fact some centers are currently using vitrification as an exclusive method. It will be necessary to wait a few years to have the same experience as with slow freezing [16].

There are 3 potential sites for transplantation: transplantation to the ipsilateral and/or contralateral ovary, into an ipsilateral and/or contralateral peritoneal pocket, and heterologous transplantation. Potential benefits of the ovary as the site of re-transplantation are that the tissue was originally taken from the same site and the transplanted sample can be located easily and removed if necessary. However, the risk of bleeding is higher and there is also a potential risk of trauma to the ovary which can be avoided by transplantation into a peritoneal pocket. In the reported series, the peritoneal window created close to the ovarian hilus and the ovarian medulla both appear to be equally efficient sites of reimplantation, at least for restoration of ovarian activity [10,16, 20] although some authors considered follicular activity in the peritoneal site to be lower than that observed on the medulla [19].

Treatment of the transplantation site during surgery is controversial. The advantages of the use sutures or fibrin glue are the secure closure the peritoneum or the ovary which ensures that the transplanted tissue will not fall out. However the sutures or other materials may produce additional trauma to surrounding tissue and the potentially high risk of adhesions and postoperative pain [18-21].

Auto transplantation of ovarian tissue in the remaining or in the contralateral ovary present more difficulty compared to peritoneal pockets, but increases the chance of getting spontaneous pregnancies and also facilitates the ultrasound monitoring of follicular growth. In our study, all four patients underwent auto transplantation in the contralateral ovary using as the adhesive material N-hexyl-2-cyanoacrylate which has a capacity greater than the fibrin glue fixation and avoids the use of sutures. No postoperative complications and difficulty in ultrasound monitoring of patients were observed. In addition we performed oocyte retrievals without difficulty.

Currently, tissue adhesives and glues are an alternative technology in clinical applications that are important both to the medical industry and surgical profession. Many of these emerging tissue adhesives could modify difficult surgical procedures by stabilizing tissue surfaces

through hemostasis, sealing of wounds, and fixation of tissue in areas inaccessible to staples, clips, and suture placement [22-23].

There are differences between synthetic (cyanoacrylates) and biological (fibrine glue) tissue adhesives. It should be clear that biological adhesives are concentrated fibrinogen and factor XIII, in addition, biological adhesives can have contamination (risk of transmission of disease). For this reason they require prior preparation (while synthetic tissue adhesives can be applied immediately after opening) and are much more expensive [24].

Synthetic cyanoacrylate tissue adhesives have been used extensively as an alternative to current conventional treatments in clinical applications and studies, including applications in thoracic, gastrointestinal, neurologic, cardiovascular, ophthalmologic, urologic and vascular surgery [25,26].

The fundamental advantages of the N-hexyl-2-cyanoacrylate are the high purity and low polymerization temperature presented, which contributes to avoid toxicity as adhesive, In the absence of impurities in the formulation, it doesn't affect its effectiveness as adhesive. This purity of these cyanoacrylate allows not having to resort to the use of stabilizers frequently in other cyanoacrylates and can be applied immediately after opening [27,28].

Although the study includes a small number of patients we demonstrated the effectiveness of the application of N-hexyl-2-cyanoacrylate at the transplantation site. In all patients ovarian function was restored and maintained for at least one year. Obviously age was an important prognostic factor because in the last 2 patients ovarian tissue was stored at earlier ages and the restoration of ovarian function was achieved earlier. In the last of transplanted patients, spontaneous pregnancy was achieved, showing that ovarian orthotopic transplant can facilitate this possibility.

In conclusion we relate our experience with the use of n-hexyl-2-cyanoacrylate as adhesive material in the orthotopic transplantation of ovarian tissue. We have proven their potential adhesive facilitating the apposition of the fragments of tissue in the ovarian medulla without affecting the restoration of ovarian activity and its effectiveness in reproductive terms.

### Authorship and contributionship

Study concept and design: FF. and JMC. Acquisition of data: JF, RS ,GC and SP. Statistical analysis: FC. and D.B. Interpretation and synthesis of data: FF and JP. Writing of the article: FF and JF. Critical revision of the article: DM,AB and MC. All authors agree with the article's results and conclusions. All authors have read, and confirm that they meet, the authorship criteria.

### Acknowledgements

None

### Financial support and sponsorship

None

### Conflicts of interest

There are no conflicts of interest

### References

1. Taylor JF, Ott MA (2016) Fertility preservation after a cancer diagnosis: a systematic review of adolescents, parents, and providers perspectives, experiences, and preferences. *J Pediatr Adolesc Gynecol* 29:585-598. [\[Crossref\]](#)

2. Wallace WH, Anderson RA, Irvine DS (2005) Fertility preservation for young patients with cancer: who is at risk and what can be offered? *Lancet Oncol* 6: 209-218. [\[Crossref\]](#)
3. Jeruss JS, Woodruff TK (2009) Preservation of fertility in patients with cancer. *N Engl J Med* 360: 902-911. [\[Crossref\]](#)
4. Rosendahl M, Andersen CY, Ernst E (2008) Ovarian function after removal of a entire ovary for cryopreservation of pieces of cortex prior gonadotoxic treatment: a follow up study. *Hum. Reprod* 23: 2475-2483. [\[Crossref\]](#)
5. Donnez J, Silber S, Andersen CY, et al. (2011) Children born after autotransplantation of cryopreserved ovarian tissue. A review of 13 live births. *Ann Med* 43: 437-450. [\[Crossref\]](#)
6. Andersen CY, Kristensen SG, Greeve T, et al. (2012) Cryopreservation of ovarian tissue for fertility preservation in young female oncological patients. *Futur Oncol* 8: 595-608. [\[Crossref\]](#)
7. Jensen AK, Macklon KT, Fedder J (2017) 86 successful births and 9 ongoing pregnancies worldwide in women transplanted with frozen-thawed ovarian tissue: focus on birth and perinatal outcome in 40 of these children. *J Assist Reprod Genet* 34: 325-336. [\[Crossref\]](#)
8. Provoost V, Tilleman K, D'Ángelo A, et al. (2014) Beyond the dichotomy: a tool for distinguishing between experimental, innovative and established treatment. *Hum Reprod* 29: 413-417. [\[Crossref\]](#)
9. Practice Committee of American Society for Reproductive Medicine (2014) Ovarian tissue cryopreservation: a committee opinion. *Fertil Steril* 101: 1237-1243
10. Donnez J, Dolmans MM (2015) Ovarian cortex transplantation: 60 reported live births brings the succès and worldwide expansion of the technique towards routine clinical practice. *J Assist Reprod Genet* 32: 1167-1170. [\[Crossref\]](#)
11. Beckmann MW, Dittrich R, Findeklee S (2016) Surgical aspects of ovarian tissue removal and ovarian tissue transplantation for fertility preservation. *Geburtsh Frauenheilk* 6: 1057-1064. [\[Crossref\]](#)
12. Gonzalez-Foruria I, Peñarrubia J, Borrás A et al. (2016) Age, independent from ovarian reserve status is the main prognostic factor in natural cycle in vitro fertilization. *Fertil Steril* 106: 342-347. [\[Crossref\]](#)
13. Schmidt KLT, Ernst E, Byskow AG, et al. (2003) Survival of primordial follicles following prolonged transportation of ovarian tissue prior to cryopreservation. *Hum Reprod* 18: 2654-2659. [\[Crossref\]](#)
14. Kawamura K, Cheng Y, Suzuki N, Deguchi M, Sato Y, et al. (2013) Hippo signaling disruption and Akt stimulation of ovarian follicles for infertility treatment. *Proc Natl Acad Sci U S A* 110: 17474-17479. [\[Crossref\]](#)
15. Suzuki N, Yoshioka N, Takae S (2015) Successful fertility preservation following ovarian tissue vitrification in patients with primary ovarian insufficiency. *Hum Reprod* 30: 608-615. [\[Crossref\]](#)
16. Silber S (2016) Ovarian tissue cryopreservation and transplantation: scientific implications. *J Assist Reprod Genet* 33: 1595-1603. [\[Crossref\]](#)
17. Van der Ven H, Liebentron J, Beckmann M (2016) Ninety-five orthotopic transplantations in 74 women of ovarian tissue after cytotoxic treatment in a fertility preservation network: tissue activity, pregnancy and delivery rates. *Hum Reprod* 31: 2031-2041. [\[Crossref\]](#)
18. Dittrich R, Hackl J, Lotz L, Hoffmann I, Beckmann MW (2015) Pregnancies and live births after 20 transplantations of cryopreserved ovarian tissue in a single center. *Fertil Steril* 103: 462-468. [\[Crossref\]](#)
19. Demeestere I, Simon P, Emiliani S, Delbaere A, Englert Y (2009) Orthotopic and heterotopic ovarian tissue transplantation. *Hum Reprod Update* 15: 649-665. [\[Crossref\]](#)
20. Donnez J, Dolmans MM, Pellicer A, (2013) Restoration of ovarian activity and pregnancy after transplantation of cryopreserved ovarian tissue: a review of 60 cases of reimplantation. *Fertil Steril* 99: 1503-1513. [\[Crossref\]](#)
21. Sanchez-Serrano M, Crespo J, Mirabet V (2010) Twins born after transplantation of ovarian cortical tissue and oocyte vitrification. *Fertil Steril* 93: 268.e11-268.e13
22. Ayyıldız SN, Ayyıldız A (2017) Cyanoacrylic tissue glues: Biochemical properties and their usage in urology. *Turk J Urol* 43: 14-24. [\[Crossref\]](#)
23. Pascual G, Rodríguez M, Mesa-Ciller C, Pérez KB, Fernández-Gutiérrez M, et al. (2017) Sutures versus new cyanoacrylates in prosthetic abdominal wall repair: a preclinical long-term study. *J Surg Res* 220: 30-39. [\[Crossref\]](#)
24. Ryu N, Thompson CC (2006) Tissue adhesives. A review. *Tech Gastrointest Endosc* 8: 33-37

25. Spotnitz WD, Prabhu R (2005) Fibrin sealant tissue adhesive--review and update. *J Long Term Eff Med Implants* 15: 245-270. [[Crossref](#)]
26. Singh V, Singh R, Bhalla A, Sharma N (2016) Cyanoacrylate therapy for the treatment of gastric varices: a new method. *J Dig Dis* 17: 392-398. [[Crossref](#)]
27. Weilert F, Binmoeller KF (2016) Cyanoacrylate glue for gastrointestinal bleeding. *Curr Opin Gastroenterol* [[Crossref](#)]
28. Pascual G, Sotomayor S, Rodriguez M (2016) Cytotoxicity of cyanoacrylate-based tissue adhesives and short-term preclinical in vivo biocompatibility in abdominal hernia repair. *PLoS One* 11: 1-22. [[Crossref](#)]